

DICLOFENAC-INDUCED MUSICAL PSEUDOHALLUCINATIONS DUE TO REDUCED PERFUSION OF THE LEFT THALAMUS IN 99M-Tc-BICISATE-SPECT

KLAWE Christoph

Department of Neurology and Neurophysiology, Hospital of the Brothers of Mercy, Nordallee 1-3, Trier, Germany.

Abstract

We describe the case of a patient with musical hallucinations after starting pain treatment with diclofenac. A 899 MBq 99m-Tc-Bicisate-SPECT performed on the day after onset of the symptoms showed a markedly reduced perfusion of the left thalamus, whereas the perfusion of the striatum remained unaltered. When diclofenac was stopped, the hallucinations also ceased. Two weeks later, the hypoperfusion of the left thalamus was hardly detectable anymore in a control SPECT with the same technique.

Key words: Musical hallucinations, diclofenac, 99-Tc-Bicisate-SPECT

Corresponding author: Christoph Klawe, c.klawe@bk-trier.de

A 57 y.o. patient was admitted for treatment of chronic pain disorder. On initial neurologic examination, nothing abnormal was detected. She was put on trimipramine in a dosage of 100 mg per day and the pain subsided gradually. In an accident in the physiotherapy training hall she luxated her shoulder and was consecutively treated with 225 mg diclofenac daily. As early as in the evening of the first day on diclofenac she described annoying musical pseudo-hallucinations which took the form of continuously repeated evergreen melodies. These could not be suppressed by any means of distraction. Moreover, she stated that she had experienced the same phenomenon during an earlier treatment course for her pain disorder with the same substance. Then, however, she did not report them for fear of taken for mentally ill. NMR imaging and an EEG during the hallucinatory state did not reveal any abnormal results. A 899 MBq

99m-Tc-Bicisate-SPECT performed on the day after onset of the symptoms, on the other hand, showed a markedly reduced perfusion of the left thalamus, whereas the perfusion of the striatum remained unaltered (Fig. 1). When diclofenac was stopped, the hallucinations also ceased. Two weeks later, the hypoperfusion of the left thalamus was hardly detectable anymore in a control SPECT with the same technique. Now only a bifrontal hypoperfusion with a slight pronounciation of the left hemisphere was detected (Fig. 2). Drug-induced musical hallucinations had been described both with tricyclic antidepressants [1] and NSAID [2]. Since the hallucinations in our patient followed to an intraindividual rechallenge, clearly diclofenac, a member of the latter group of drugs, seemed to be responsible for the symptoms. The central inhibitory effects of NSAID on thalamic neurotransmission were demonstrated [3]. In functional imag-

ing studies of patients with musical hallucinations, mainly disturbances of the regional cerebral blood flow in the temporal lobes are found [4]. Auditory hallucinations in patients with schizophrenia, however, were –among other findings– shown to be linked with an increased perfusion of the right thalamus [5]. An asymmetrical inhibition of

thalamic functioning (here the left) for what reasons ever (e.g. NSAID induced) could therefore explain a dysequilibrium in lateralization (relatively increased perfusion of the right thalamus) that results in auditory hallucinations. The SPECT finding in our patient may reflect such a mechanism.

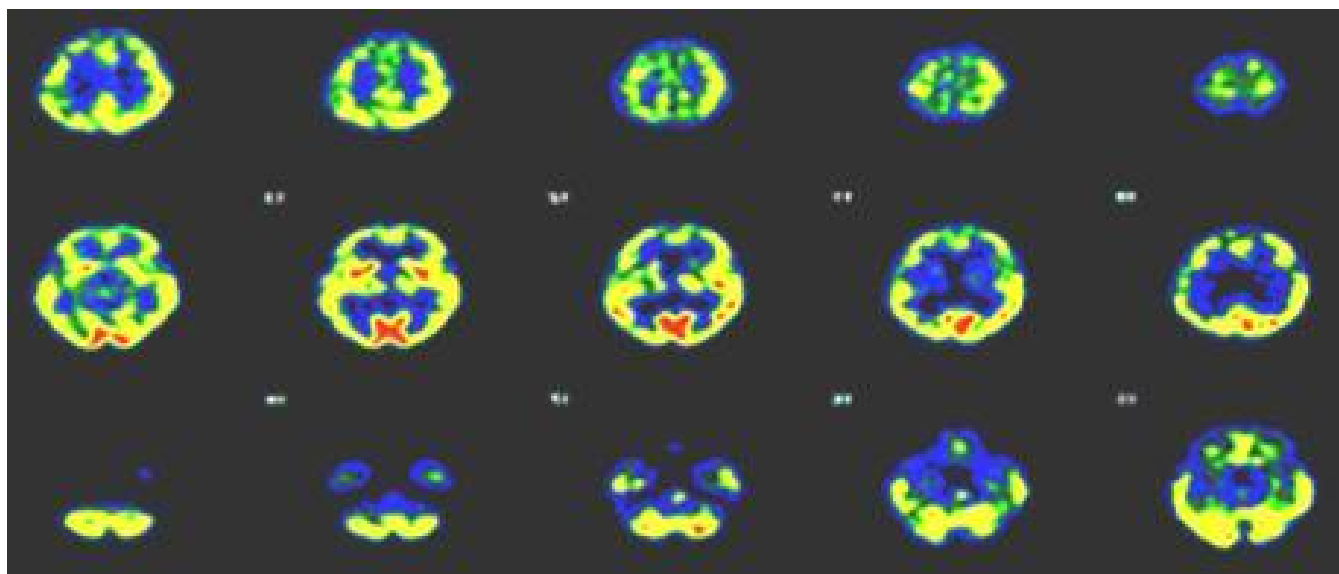


Fig. 1. Reduced perfusion of the left thalamus in a 99m-Tc-Bicisate-SPECT

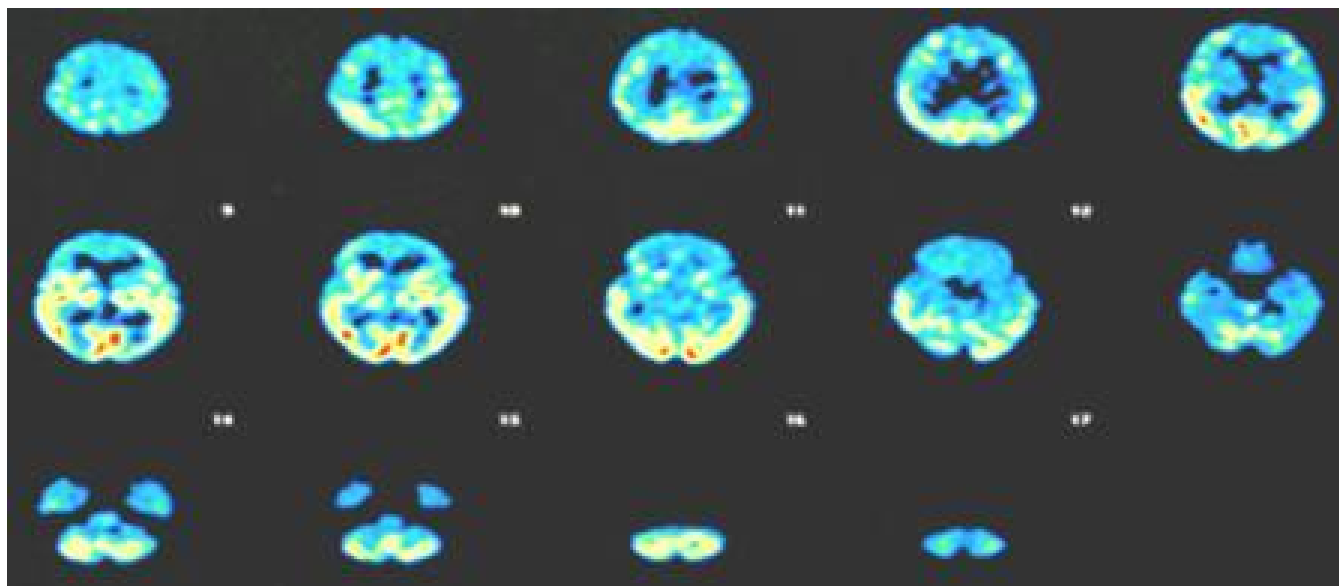


Fig. 2. The difference in thalamic perfusion is not detectable anymore after the hallucinations had ceased

Resumo

Ni priskribas la kazon de malsanulino kun muzikaj halucinoj, kiuj komencis post ekstraktado de doloro per diklofenako. 899 MBq 99m-Tc-Bicisato-

SPECT, kiu estas farita unu tagon post la komenco de la simptomoj montris rimarkinde reduktitan sangvofluon en la regiono de la maldekstra talamo, sed la sangvofluo en la striato ne estis ŝanĝita. Kiam la donado de diklofenako estis haltita, ankaŭ la

halucinoj ĉesis. Du semajnoj poste, la malplia sangvofluo en la maldekstra talamo estis apenau rimarkebla en kontrola SPECT kun la sama tekniko.

References

- 1 Gordon, A.G. Tricyclic-induced musical hallucinations. *Biol Psychiatry* 1996; 40:309-310.
- 2 Lantz MS, Giambanco V. Acute onset of auditory hallucinations after initiation of celecoxib therapy. *Am J Psychiatry* 2000; 157:1022-1023.
- 3 Jurna I, Brune K. Central effect of the non-steroid anti-inflammatory agents, indomethacin, ibuprofen, and diclofenac, determined in C fibre-evoked activity in single neurones of the rat thalamus. *Pain* 1990; 41:71-80.
- 4 Erkwow R, Ebel H, Kachel F, et al. 18FDG-PET and electroencephalographic findings in a patient suffering from musical hallucinations. *Nuklearmedizin* 1993; 32:159-163.
- 5 Shergill SS, Brammer MJ, Williams SC, Murray RM, McGuire PK. Mapping auditory hallucinations in schizophrenia using functional magnetic resonance imaging. *Arch Gen Psychiatry* 2000; 57:1033-1038.